

Solitary Median Maxillary Central Incisor: A Family Showing Dominant Inheritance and Mild Variable Expression

Yousif I. Omari, Ahmad S. Qadri and Oraib Y. Omari*

ABSTRACT

We report on outbred Jordanian family with three children, two girls and one boy, affected with Solitary Median Maxillary Central Incisor (SMMCI) and associated with minor midline anomalies. The two affected sisters had absence of frenulum. The boy had narrow high arch palate, depressed nasal bridge and broad nasal groove. The three children had no additional physical anomalies, were of normal learning abilities, and had a normal karyotype. The high recurrence of this SMMCI syndrome in one family together with the clinical findings and initial pedigree analysis suggest that SMMCI is a true pleiotropic and our patients may represent a previously undescribed autosomal dominant inheritance which leads to minor midline anomalies.

Keywords: Solitary Central Incisor; Genetic Disease; Dental Disease; Family Study.

1. INTRODUCTION

Solitary Median Maxillary Central Incisor (SMMCI)(OMIM number:#147250) is one of the human developmental anomalies which has been reported as an isolated morphogenic defect or associated with other anomalies (Rappaport *et al.*, 1977; Berry *et al.*, 1984; Kociss, 1990; Aughton *et al.*, 1991; Walker *et al.*, 1996; Vanelli *et al.*, 1997; Lo *et al.*, 1998; Suthers *et al.*, 1999; Nanni *et al.*, 2001; Manni *et al.*, 2003; Mendoza *et al.*, 2005). Of the patients with SMMCI, 69 % had short stature, 48 % growth hormone deficiency, 23 % pituitary absence and 17 % had del (18 p -) or r (18) (Lo *et al.*, 1998). The etiological explanation of the appearance of a single incisor in place of two teeth may be related to fusion of two neighboring teeth or to agenesis of a tooth germ (Mass and Sarnat, 1991). Little is known about its pattern of inheritance (Kopp, 1967; Pfeiffer, 1969; Dolan *et al.*, 1981; Masuno *et al.*, 1990; Miura *et al.*, 1993; Muenke, 1994; Belloni *et al.*, 1996; Nanni *et al.*, 2001). However, the present study reports an outbred Jordanian family with 3 children affected with SMMCI - an extremely rare occurrence- and associated with mild

variable expression. The spectrum of anomalies and associated features present in these 3 children is described, and the literature related to the features, including genetic studies in these conditions, is reviewed.

2. MATERIALS AND METHODS

A family with Solitary Median Maxillary Central Incisor (SMMCI) was studied. Three cases, two girls and one boy, are presented with morphologically normal single maxillary central incisor. Their ages at presentation were 9 years (case no. 1), 10 years (case no. 2) and 6 years (case no. 3). Clinical examination revealed a single median maxillary central incisor of normal crown dimensions, situated in the midline of the alveolar bone. The crown of the incisor tooth has an incisal ridge as that in the normal central and lateral incisors. The crown and the root join at the cemento-enamel junction (cervical line). The tooth appeared normal in color and had no enamel defects. Radiographic examination showed that the root portion of the tooth appears to be single with one apex and had pulp canal. Both the mother and the father were clinically normal.

All 3 cases of SMMCI syndrome had been fully diagnosed. Full personal and family histories have been taken, dental examination have been included, radiographs (panoramic and periapical films) have been produced, laboratory investigation including pituitary

* Department of Biological Sciences, University of Jordan, Amman, Jordan(1); Al-Qadri Orthodontic and Dental Center, Amman, Jordan(2,3). Received on 31/10/2006 and Accepted for Publication on 12/3/2007.

hypofunction, CNS, ophthalmologic were performed and blood samples were taken for chromosome analysis.

3. RESULTS

The study presents an outbred Jordanian family with 3 children affected with Solitary Median Maxillary Central Incisor (SMMCI) (Fig. 1). Table (1) describes the spectrum of anomalies and associated features present in these three children. The literature related to the features is reviewed. The Growth Hormone (GH) level was estimated to be within the normal limits: 0.24, 0.53 and 0.70 ng/ml for case no. 1, 2 and 3, respectively. The three related children have SMMCI associated with minor midline defects. The boy had minor facial anomalies. This includes depressed nasal bridge, broad nasal groove and narrow high arch palate. The two sisters had the

combined findings of SMMCI and absence of frenum. The three children had no additional physical anomalies, were of normal intelligence, and had a normal karyotype. There were no changes to other organs. Almost all the malformations mentioned in the first column of Table (1) have not been reported in our three cases. A relationship between absent tooth and abnormal morphology of remaining teeth has not been observed within the affected members of the family studied.

Clinical study indicates the presence of a single median maxillary central incisor situated in the midline of the alveolar bone. Radiographic examination showed that the permanent lateral incisors could be seen on both sides of the tooth as in case no. 2 (Fig. 2). The primary and permanent lateral incisors could also be seen on both sides of the tooth as in cases no. 1 and no. 3 (Fig. 2). Moreover, all permanent teeth were present in all of our patients.

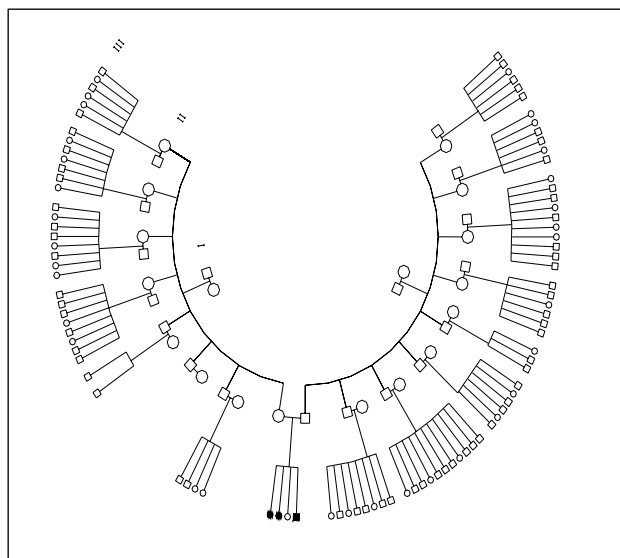


Figure 1. Pedigree of solitary maxillary central incisor.

4. DISCUSSION

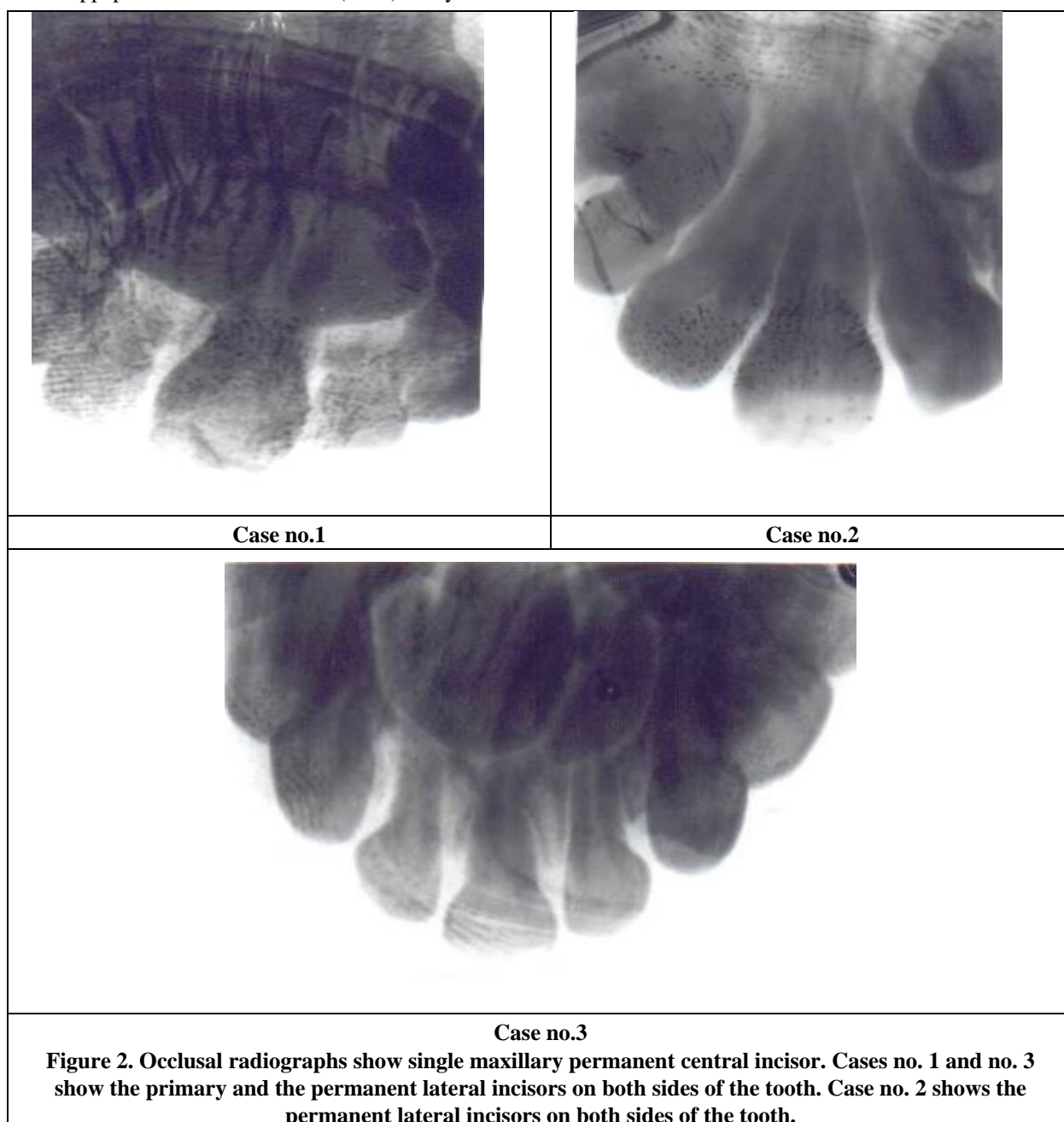
The presence of a solitary median maxillary central incisor was first reported by Scot in 1958. This syndrome has been reported as an isolated morphognostic defect or in combination to additional developmental disorders: hypopituitarism, holoprosencephaly, ocular coloboma, short stature, CNS anomaly and chromosome abnormalities (Rappaport *et al.*, 1977; Berry *et al.*, 1984; Kocsis, 1990; Aughton *et al.*, 1991; Walker *et al.*, 1996; Vanelli *et al.*, 1997; Lo *et al.*, 1998, 1999; Nanni

et al., 2001). In this work we report the absence of upper first incisor associated with minor midline abnormalities (Table 1) and analyzed in a Jordanian family representing the first, and to our knowledge, probably the only familial case with 3 children, two girls and a boy, associated with SMMCI (Fig. 1). The first and most easily recognized anomaly associated with the syndrome in this family is the median maxillary single incisor tooth. Two other features that may be noted early are an absence of a labial frenulum (in girls), and a narrow high arch palate (in a boy)

(Table 1). The boy had minor midline anomalies: depressed nasal bridge and broad nasal groove. Both affected sisters and their brother had no detectable other physical anomalies, and there were no changes to other organs (Table 1). The three children were of normal intelligence and had a normal karyotype analysis. Cases with this condition raised the possibility of the existence of a new syndrome and should undergo a careful genetic evaluation. In this connection, SMMCI syndrome was reported previously in Jordan (Yassin and El-tal, 1998).

Short stature, with growth hormone deficiency, has been previously reported with a single maxillary central incisor. Rappaport and his coworkers (1976) analyzed 7

cases of SMMCI with short stature, five of whom have proven deficiencies of growth hormone. This association was later confirmed by Vanelli *et al.*, 1997, Lo *et al.*, 1998, and Mendoza *et al.*, 2005. In one of these studies, Lo and his coworkers analyzed 40 cases of SMMCI. Of these cases with SMMCI, 69% had short stature and 48% growth hormone deficiency. Other studies displayed short stature but normal growth hormone levels (Rappaport *et al.*, 1976; Parker and Vann, 1985; Bamba *et al.*, 1989). The present study reports 3 related children with SMMCI in a Jordanian family, two sisters and one brother, whose height was normal and their growth hormone levels were within normal limits.



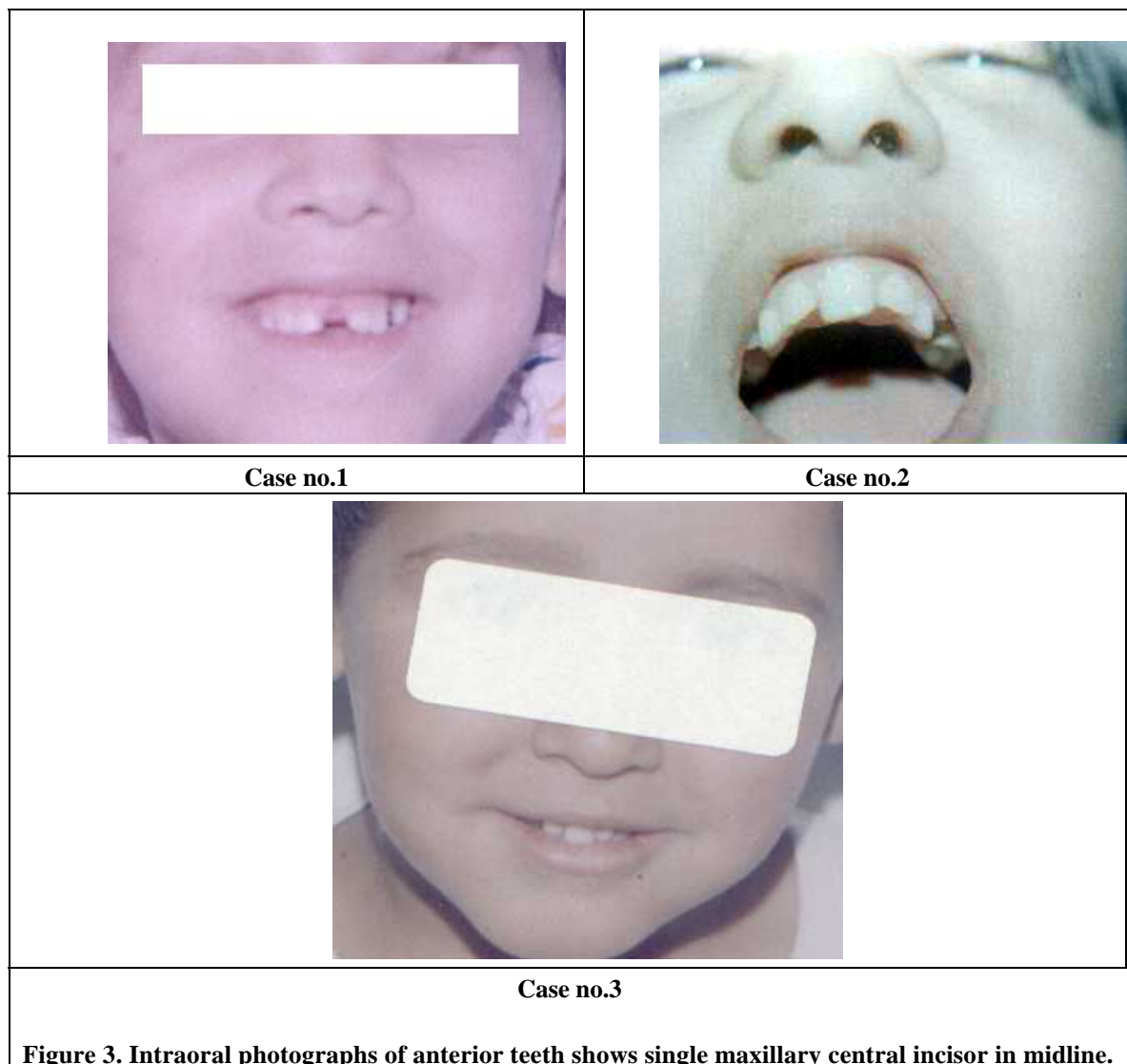


Figure 3. Intraoral photographs of anterior teeth shows single maxillary central incisor in midline.

The SMMCI syndrome in the Jordanian family is fully expressed in 3 out of 4 (Fig. 1). This number was a far greater number than would have been expected in any chance in one family. Consequently, this high incidence of SMMCI in this family is in favor of a genetic cause.

Agenesis of one or more teeth is one of the most common human developmental anomalies. The incidence of tooth agenesis varies with tooth class. The third molar is the most frequent at 20 % (Jorgenson, 1980; Stewart *et al.*, 1982; Winter and Brook, 1986). Next in frequency of absence are the upper lower second premolar (3.4 %) followed by the maxillary lateral incisors (2.25 %). Familial tooth agenesis is transmitted as an autosomal dominant, recessive autosomal, sex-linked to X or Y,

polygenic, or chromosome aberration (Pfeiffer, 1969; Dolan *et al.*, 1981; Masuno *et al.*, 1990; Miura *et al.*, 1993; Muenke, 1994; Belloni *et al.*, 1996; Mendoza *et al.*, 2005). Affected members within a family often exhibit significant variability with regard to the location, symmetry and number of teeth involved (Miura *et al.*, 1993; Belloni *et al.*, 1996; Roessler *et al.*, 1996). In the present study, the affected members do not exhibit such variability. Moreover, a relationship between the absence of maxillary central incisor and abnormal morphology of remaining teeth has not been observed in our patients as it has been indicated by others (Lo *et al.*, 1997; Mendoza *et al.*, 2005). This may imply a more general underlying genetic cause and that agenesis is more than just a localized chance event. Consequently, an attempt was

made to study the pattern of inheritance of the unilateral absence of upper first incisor in our patients. In the family of these patients, SMMCI is fully expressed in 3 out of 4. The pedigree of this family is shown in figure 1. Analysis of it reveals none of the affected persons' grandparents and neither their parents nor any of their then -living relatives had SMMCI, so the trait (SMMCI) probably first appeared as a spontaneous mutation in one of the X chromosome or autosomes before affected patients inherited it from one of their parents. The trait (SMMCI) is likely to be de novo mutation of a dominant gene in a germ cell or gonad tissue from genetically normal parents. Moreover, it is important to indicate that as the trait appears in both males and females, the Y - linked inheritance was excluded.

Although the evidence of tooth agenesis in favor of a genetic cause is generally convincing, there are some unanswered questions, perhaps the most pressing are these: where is the gene? What is its product? and what is the pathogenesis of the trait? A follow-up study may provide additional information for this family to answer these questions. However, the wide variation in the features associated with SMMCI (Table 1) and the present SMMCI condition associated with minor midline anomalies in the Jordanian family led one to believe that the Jordanian condition might represent a previously undescribed autosomal or X- linked dominant inheritance. This condition is probably one of the mutations in the SMMCI gene that does not lead to drastic abnormalities.

5. CONCLUSIONS

Considering our cases and previous reports of

SMMCI, it appears that as the solitary median maxillary central incisor can occur as an isolated anomaly or in combination to additional anomalies; it can be used as a diagnostic clue to other medical problems. Therefore, any child with SMMCI should be referred for a full medical examination: a detailed pedigree analysis, growth hormone estimation, CT examination of the brain, assessment of intelligence quotient, and chromosome analysis in order to enable the clinicians to determine the real risk associated with SMMCI which, once identified, may require specialist care and a cure may be forthcoming. It is hoped that early detection of SMMCI will aid in the diagnosis of other affected family members, which may help the parents to overcome the disease. The results of the present study and previous reports of SMMCI syndrome indicate that the presence of this syndrome should not be considered as a simple dental anomaly, since it may be associated with other clinical characteristics and more complex craniofacial malformations.

By the close of the study, no one of our patients developed definite anomaly. However, longer follow-up is required to know if any anomaly may exist in association with the SMMCI syndrome.

6. ACKNOWLEDGMENTS

The authors thank the following persons for their contributions to the study and care of the children: Dr. Omar N. Shunnar, Otolaryngologist; Dr. Kareman S. Kadri, Pathologist; Dr. Wael Alam-Eddin, Pediatrician; and Dr. Fallouh A. Issa, Ophthalmologist. Our thanks also go to the staff of the Private Orthodontic and Dental Center for assistance and support.

Table (1) Solitary maxillary central incisor: associated features.

Associated features	Case number		
	1	2	3
Sex	F	F	M
Facial malformation			
Depressed nasal bridge ^{1,2,12,19,25,26}	-	-	+
Broad nasal groove ^{1,27}	-	-	+
Deviated nasal septum ¹⁸	-	-	-
Congenital nasal stenosis ^{28,29,38}	-	-	-
Anosia ³⁰	-	-	-
Hyposmia ³⁰	-	-	-
Choanal atresia ^{31,32}	-	-	-
Slanting palpebral fissures ^{18,30,33}	-	-	-
Hypotelorism ^{1,28,30}	-	-	-
Convergent strabismus ³⁰	-	-	-
Visual defects ³¹	-	-	-
Thick pinea and small pit ⁴	-	-	-
Malformed ear lobes ³³	-	-	-
Oral cavity			
Labial frenum	-	-	+
Narrow high arch palate ^{5,25,28}	-	-	+
Solitary maxillary central incisor ^{27,33,34}	+	+	+
Genitalia			
Undescended testis (Cryptorchism) ^{18,27}	-	-	-
Hypospadias ³⁰	-	-	-
Micropenis ³⁰	-	-	-
CNS			
Microcephaly ^{30,33,35,36}	-	-	-
Spina bifida ³¹	-	-	-
Holoprosencephaly ^{2,26,37,38}	-	-	-
Skeletal system			
Scoliosis ^{27,36}	-	-	-
Cervical/thoracic spinal abnormality ³⁰	-	-	-
Partial syndactyly toes ¹	-	-	-
Absence of two sacral vertebra ²⁷	-	-	-
Mental status			
Slow learning abilities ^{18,30}	-	-	-
Endocrine system			
Growth hormone deficiency ^{1,25,30}	-	-	-
Short stature ^{25,39}	-	-	-
Cardiac abnormalities ^{27,31,36,38}	-	-	-
Chromosome abnormalities			
del(18p11.3) ^{4,12,40,41}	-	-	-
r(18) ^{7,17,42}	-	-	-
del(7q32 → qter) ^{13,39}	-	-	-
47,xxx ¹⁴	-	-	-

M=male; F=female; +=feature present; -=feature absent.

REFERENCES

- Aris, H. and Ward, R. F. 1992. Congenital Nasal Pyriform Aperture Stenosis Isolated Abnormality Vs. Developmental field defect, *Arch Otolaryol Head Neck Surg.*, 118: 989-991.
- Artman, H. G. and Boyden, E. 1990. Microphthalmia with Single Central Incisor And Hypopituitarism, *J. Med. Genet.*, 27: 192-193.
- Aughton, D. J., Al Saadi, A. A. and Transus, D. J. 1991. Single Maxillary Central Incisor in a Girl with Del (18p) Syndrome, *J. Med. Genet.*, 28: 530-532.
- Bamba, S., Terayama, H., Ikeda, M. and Ogala, K. 1989. Clinical Evaluation of Six Patients with a Single Maxillary Central Incisor, *Japanese Journal of Pediatric Dentistry*, 10: 52-66.
- Bartholomew, D. W., Jabs, E. W., Levin, L. S., Ribovich, R. 1987. Single Maxillary Central Incisor and Coloboma In Hypomelanosis of Ito. *C/in. Genet.*, 32: 370-373.
- Belloni, E., Muenke, M. Roessler, E. 1996. Identification of Sonic Hedgehog as a Candidate Gene Responsible for Holoprosencephaly, *Nat. Genet.*, 14: 353-356.
- Berry, S. A., Pierpoint, M. E. and Gorlin, R. J. 1984. Single Central Incisor in Familial Holoprosencephaly, *J. Pediatr.*, 104: 877-880.
- Boudaillier, B., Morichen-Del Vallez, N., Goldfarb, A., Pautard, J. C. and Lenaerts, C., Piussan, C. 1983. Incisive Superieure Unique, Hypopituitarisme et Anomalie Chromosomique Monosomic 18p., *J. Genet. Hum.*, 31: 329-342.
- Brown, O. E., Myer, C. M. and Manning, S. C. 1989. Congenital Nasal Pyriform Aperture Stenosis, *Laryngoscope*, 99: 86-91.
- Camera, G., Bovone, S., Zucchinetti, P., Puzzolo, S., Giuota, F. 1992. Incisivo Mascellare Centrale Unico Holoprosencefalia, *Pathologica*, 54: 425-428.
- Dolan, L., Wilson, K. and Wilson, W. 1981. 18p- Syndrome with a Single Central Maxillary Incisor, *J. Med. Genet.*, 18: 396-398.
- Ellisdon, P. S. and Marshall, K. F. 1970. Connation of Maxillary Incisors. *Brit. Dent. J.*, 129: 16-21.
- Fleming, P., Nelson, J. and Gorlin, R. J. 1990. Single MAXILLARY CENTRAL INCISOR in Association with Midline Anomalies, *Br. Dent. J.*, 168: 476-479.
- Frint, S. G., Schrandner-Stumpel, C. T., Schoenmaker, E. F., Engelen, J. J., Reekers, A. B. A., Van den Neucker, A.M., Smeets, E., Devlieger, H. and Fryns, J. P. 1998. Strong Variable Clinical Presentation in 3 Patients with 7q Terminai Deletion, *Genet. Counsel.*, 9: 5-14.
- Fulstow, E. D. 1968. The Congenital Absence of Upper Central Incisor Report of a Case, *Br. Dent. J.*, 124: 186-188.
- Hall, R. K. 1994. *Paediatric Orofacial Medicine and Pathology*, London: Chapman and Hall, 121.
- Hall, R. K., Bankier, A., Aldred, M. J., Kan, K., Lucas, J. O., Graeme, A. and Perks, B. 1997. Solitary Median Maxillary Central Incisor, Short Stature, Choanal Atresia/ Midnasal Stenosis (SMMCI) Syndrome, *Oral Surg Oral Med Oral Path.*, 84: 651-661.
- Jorgenson, R. J. 1980. Clinician's View of Hypodontia, *J. Am. Dent. Assoc.*, 101: 283-286.
- Kjaer, I., Becktor, K. B., Lisson, J., Gormsen, C. and Russell, B. G. 2001. Face, Palate, and Craniofacial Morphology in Patients with a Solitary Median Maxillary Central Incisor, *Eur. J. Orthod.*, 23(1): 63-73.
- Kjellin, L. B., Kaiserman, K. B., Curran, S. G., Geffner, M. E. 1999. Aplasia of Internal Carotid Artery and Hypopituitarism, *Pediatr. Radio.*, 29: 588.
- Kocsis, S. G. 1990. A Single Central Maxillary Incisor and Hypopituitarism. *J. Med. Genet.*, 27: 192-193.
- Kocsis, S. G. 1994. A Single Central Maxillary Incisor in the Midline as a Mild form of Holoprosencephaly, *Fogorv. Sz.*, 87: 63-70.
- Kopp W. 1967. A Hereditary Congenitally Missing Maxillary Central Incisor, *Oral Surg Oral Med Oral Pathol.*, 24: 367.
- Lo, F. S., Lee, K. S., Chen, L. S., Hung, H. Y., Hsu, C. H., Lin, S. P. and Lee, Y. J. 1991. Congenital Nasal Pyriform Aperture Stenosis: A Diagnostic Clue to Solitary Maxillary Central Incisor Prior to Eruption in Three Infants, *J. Otolaryngol.*, 28(1): 51-53.
- Lo, F. S., Lee, Y. J., Lin, S. P., Shen, E. Y., Huang, J. K. and Lee, K. S. 1997. Medical Genetics: Solitary Maxillary Central Incisor and Congenital Nasal Pyriform Aperture Stenosis, *European Journal of Pediatrics*, 157: 39-40.
- Lo, F. S., Lee, Y. J., Lin, S. P., Shen, E. Y., Huang, J. K. and Lee, K. S. 1998. Solitary Maxillary Central Incisor and Congenital Nasal Pyriform Aperture Stenosis, *Eur. J. Pediatr.*, 157(1): 39-44.
- Luisa, N., Ming, J. E., Du, Y., Hall, R. K., Aldred, M., Bankier, A., Muenke, M. 2001. SHH Mutation is Associated with Solitary Median Maxillary Central Incisor: A Study of 13 Patients and Review of the Literature, *American J. Med. Genet.*, 102(1): 1-10.
- Manni, M., Cusano, R., De Biasio, P., Caroli, F., Lerone, M. and Camera, G. 2003. Previously Undescribed Nonsense

- Mutation in SHH Caused Autosomal Dominant Holoprosencephaly with Wide Intrafamilial Variability, *Am. J. Med. Genet.*, 117A: 112-115.
- Mass, E. and Sarnat, H. 1991. Single Maxillary Central Incisors in the Midline, *Journal of Dentistry for Children*, 58: 413-416.
- Masuno, M., Fukushima, Y., Sugio, Y., Ikeda, M., Kuroki, Y. 1990. Two Unrelated Cases of Single Maxillary Incisor with 7q Terminal Deletion, *Japanese Journal of Human Genetics*, 35: 311-317.
- Mendoza, VDM., Fragosa, RTA. and Yamamoto, NA. 2005. Solitary Medium Maxillary Central Incisor Syndrome and Fusion of Permanent Mandibular Central Incisor, *Rev Odont Max.*, 9(1): 37-41.
- Miura, M., Kato, N., Kojima, H. and Oguchi, H. 1993. Triple X Syndrome Accompanied by Single Maxillary Central Incisor : Case Report, *Pediatr Dent.*, 15: 214-217.
- Muenke, M. 1994. Linkage of a Human Malformation, Familial Holoprosencephaly, to Chromosome 7 and Evidence for Genetic Heterogeneity, *Proc. Natl and Acad Sci.*, USA 91: 8102-8106.
- Nanni, L., Ming, J.E., Du, Y., Hall, R. K., Aldred, M., Bankier, A. and Muenke, M. 2001. SHH Mutation is Associated with Solitary Median Maxillary Central Incisor: a Study of 13 Patients and Review of the Literature, *Am. J. Med. Genet.*, 102(1): 1-10.
- Parker, P. R. and Vann, W. F. 1985. Solitary Maxillary Central Incisor: Clinical Report. *Pediatr. Dent.*, 7: 134-136.
- Pfeiffer, R. A. 1969. Sporadisch Autosomale Defizienz (45, XX, D2- 18-) t (D2.18) Bei Einem 5-Jährigen Mädchen, *Helv Paediat Acta*, 24: 167-173.
- Rappaport, E. B., Ulstrom, R. A., Gorlin, R. J. 1976. Monosuperoincisivodontic Dwarfism, *Birth Defects*, 12(5): 243-245.
- Rappaport, E. B., Ulstrom, R. A., Gorlin, R. J., Lucky, A. W., Colle, E. 1977. Solitary Maxillary Central Incisor and Short Stature, *J. Pediatr.*, 91: 924-928.
- Rappaport, E. B., Ulstrom, R. A., Gorlin, R. J., Lucky, A. W. and Colle, E. 1977. Solitary Maxillary Central Incisor and Short Stature, *J. Pediatr.*, 91: 924-928.
- Roessler, E., Belloni, E., Gaudenz, K., et al. 1996. Mutations in the Human Sonic Hedgehog Gene Cause Holoprosencephaly, *Nat Genet.*, 14: 357-360.
- Scott, D. C. 1958. Absence of Upper Central Incisor. *Br. Dent J.*, 104: 247.
- Simon, A. R. and Roberts, M. W. 1993. Solitary Incisor Syndrome and Holoprosencephaly, *J. Clin. Pediatr. Dent.*, 17: 175-177.
- Stewart, R. E., Witkop, C. J. and Bixier, D. 1982. The Dentition. In: Stewart, R. E., Barber, T. K., Troutman, K. C., Wei, S. H. V., Editors. *Pediatric Dentistry: Scientific Foundations and Clinical Practice*. St. Louis: C. V. Mosby; 87-134.
- Suthers, G., Smith, S. and Springbett, S. 1999. Skewed Sex Ratio in Familial Holoprosencephaly and in People with Isolated Single Maxillary Central Incisor, *J. Med. Genet.*, 36: 924-926.
- Taine, I., Goizet, C., Wen, Z. Q., Chateil, J. F., Bottin, J., Saura, R. and Lacombe, D. 1997. 18p Monosomy with Midline Defects and a De Novo Satellite Identified by FISH, *Ann. Genet.*, 40: 158-163.
- Tavin, E., Stecker, E. and Marion, R. 1994. Nasal Pyriform Aperture Stenosis and the Holoprosencephaly Spectrum. *Int. J. Pediatr. Otorhinolaryngol.*, 28: 199-204.
- Vanelli, M., Bernasconi, S., Balestrazzi, D. 1997. Incisive Superieure Unique Et Deficit en STH, *Archives of French Pediatrics*, 37:321-322.
- Walker, P. J., Colley, A., Crock, P. A. and Rack, M. P. 1996. Congenital Nasal Pyriform Apertur Stenosis with a Single Central Maxillary Incisor. *Aust. J. Otolaryngol.*, 2(3): 283-286.
- Wesley, R. K., Hoffman, W. H., Perrin, J., James, R. and Delaney, J. Solitary Maxillary Central Incisor and Normal Stature, *Oral surg Oral Med Oral Path.*, 46: 837-842.
- Winter, G. H. and Brook, A. H. 1986. Tooth Abnormalities. In: Rowe, A. H. R., Editor. *A Companion to Dental Studies*, 4: Clinical Dentistry, Oxford: Blackwell Scientific Publications, 55-103.
- Yassin, O. M. and El-Tall, Y. M. 1998. Solitary Maxillary Central Incisor in the Midline Associated with Systemic Disorders. *Oral Surg Oral Med Oral Path.*, 85(5): 548-550.

:

*

(3 2)

(1)

*

.2007/3/12

2006/10/31