

Clinicopathological Study of 55 Cases of Immunobullous Diseases in Jordan

*Awad Al-Tarawneh*¹

Abstract

Background: Immunobullous skin diseases are a serious group of skin disorders with variable presentations that need to be diagnosed early for better prognosis. A proper clinical and histopathological evaluation is needed for correct diagnosis, so it is an important issue to share experience and to highlight this hot spot in dermatology.

Objective: To have a clinical and histopathological insight into the immunobullous skin diseases as a group to show their distribution in our region and to share experience for proper early diagnosis.

Material and Methods: All cases of immunobullous skin diseases that had been diagnosed clinically and histopathologically at referral centers in Jordan, Amman (King Hussein Medical Center, Jordan University hospital) and in private practice from Jan. 2000 to Jan. 2012 were included in this retrospective study. All cases were analyzed clinically and histopathologically. Hematoxylin and Eosin stained sections were used for histopathological analysis. Immunofluorescence study was done on 16 cases only and Tzanck smear examination after staining with Giemsa stain was done on 5 cases.

Results: From Jan. 2000 to Jan. 2012 a total number 55 cases of different immunobullous skin diseases had been diagnosed clinically and histopathologically from a total number of 2156 skin biopsies that had been performed for different reasons and examined during that period of time.

There were 21 male patient and 34 female patients with M:F ratio 1.2: 2. Age range of the patients is 4-85 yr. The distribution of different immunobullous diseases in decreasing frequency was; bullous pemphigoid 24 patients (44%), Pemphigus vulgaris 14 patients (25%), Pemphigus foliaceus 5 cases (9%), Pemphigoid gesatationis 4 patients (7%), dermatitis herpetiformes 3 patients (5%) chronic bullous dermatosis of childhood 2 patients (8%), pemphigus erythematosus, one patient (4%), linear IgA dermatosis, one patient (4%), and lichen planus Pemphigoides one patient (4%). Histopathological features were conclusive in most of the cases. Tzanck smear test was a helpful test in cases of pemphigus group. The study reveals a rare form of pemphigus vulgaris as pemphigus with scalp lesions only. Rare histopathological features of bullous pemphigoid including cell poor blister and festooning were also seen.

Conclusion: Immunobullous skin diseases are serious skin diseases that affect all age groups. Proper clinical and histopathological examination is essentially conclusive for diagnosis. In some cases immunofluorescence study is needed for diagnosis. Simple bedside test like Tzanck smear test is helpful in some cases

Keywords: Immunobullous disease, Jordan.

(J Med J 2017; Vol. 51 (1): 1- 15)

Received

Nov. 23, 2015

Accepted

July 25, 2016

1. Consultant Dermatologist and Dermatopathologist, Assistant Professor, Faculty of Medicine, Mu`tah University, Jordan.

* Correspondence should be addressed to:

Awad Al-Tarawneh, MD

E-mail: drawadt2005@yahoo.com

Introduction

Bullous skin diseases are a relatively rare group of skin diseases, but with a relatively high morbidity and mortality if left untreated, so they need to be diagnosed and treated early in their course.

Blistering immunobullous skin disorders have been known for long time ago. But until recently, a clear classification of these diseases based upon clinical, histopathological criteria and the targeted antigen in the skin, was established with the aid of detailed microscopic examination, immunofluorescence studies, electron microscopy and molecular biology^{1,2}. Proper clinical and histopathological examination are usually diagnostic in most of cases. Histopathological examination is a must for diagnosis. Confirmatory studies, such as immunofluorescence, are important in the diagnosis of some cases when histopathological features are not diagnostic or inconclusive.

Materials and methods

All cases of immunobullous skin diseases with a confirmed diagnosis clinically and histopathologically that we have seen from Jan. 2000 to Jan. 2012 were included in our retrospective study.

Clinical and histopathological analysis for all confirmed immunobullous skin diseases cases was done. There were 55 cases of different immunobullous skin diseases out of a total number of 2156 skin biopsies that had

been taken for different reasons and examined in two referral centers in Jordan (King Hussein Medical Center and Jordan University Hospital) and in private practice in Amman.

The clinical analysis included the age of the patients, type of skin lesions, distribution of the lesions and associated diseases.

Histological analysis included level of the split, blister contents, adjacent epidermal changes, type of the inflammatory infiltrate and rare and unusual histological presentations.

Skin biopsies were sent and fixed in 10% formalin solution. Sections were stained with Hematoxylin and Eosin for routine histology and deeper cuts were done⁽⁴⁾.

Immunofluorescence study was done on (16) cases only as needed and whenever possible. Tzanck smear was done for (5) cases to look for acantholytic cells, where the material was taken from the floor of the blister after derroofing it, then smeared on a glass slide, stained with Giemsa stain and examined under light microscopy.

Results

From Jan. 2000 to Jan. 2012, out of a total 2156 skin biopsies that had been taken for different reasons, there were 55 cases of Immunobullous (blistering) skin diseases with patient age range from 4-85 years of old, accounting for 2,6% of all skin biopsies.

Table 1 shows the distribution of the various forms of immunobullous skin diseases in our study.

Table 1. Distribution of immunobullous skin diseases in this study

Disorder	Number of cases	Percentage
Bullous Pemphigoid	24	44%
Pemphigus vulgaris	14	25%
Pemphigus foliaceus	6	11%
Pemphigoid gestationis	4	7%
Dermatitis herpetiformes	3	5%
Chronic bullous disease of childhood	2	4%
Linear IgA disease	1	2%
Lichen planus Pemphigoides	1	2%
Total	55	100%

As table 1 shows, the majority of our patients have Bullous Pemphigoid (44%) or pemphigus vulgaris (25%). Table 2 and 3 show the results of clinical and histopathological analysis of bullous

pemphigoid cases respectively. Direct immunofluorescence study was done on 5 cases only of bullous pemphigoid cases and all 5 cases were positive for homogenous linear deposits of IgG and C3 at dermo-epidermal junction.

Table 2. Clinical characteristics of Bullous pemphigoid cases

Feature on presentation	Number of patients	Percentage
Sex M	12	50%
F	12	50%
Itching	18	75%
Tense blister	23	92%
No Blister	1	8%
Mucous membrane involvement	1	4%
Distribution of lesion:		
-trunk and chest	11	46%
- extremities	19	79%
Urticarial lesions	12	50%
Eczematous lesions	10	41%
Age of onset:		
-<30 yrs.	1	4%
-30-50yr.	2	8%
->50yr.	21	88%

Associated disease D.M	5	24%
Carcinoma (colon carcinoma)	1	4%

Table 3. Histopathological changes of bullous pemphigoid

Feature	Histopathological changes	Number of cases	Percentage
Level of split	-Subepidermal	23	96%
	-No frank blister	1	4%
Bullae content	Eosinophils Neutrophils, fibrin	24	100%
Adjacent epidermis	Spongiosis eosinophilic spongiosis	9	38%
		6	25%
Involvement of adnexae	Spongiosis	5	21%
Dermal infiltrate	Cell rich; Neutrophils eosinophils and lymphocyte	23	96%
	Cell poor (very sparse) inflammatory cells	1	4%
Others	Papillary dermal edema	24	100%
	Regeneration of epithelium in the floor	4	17%

Table 4 and 5 show the results of clinical and histopathological analysis of pemphigus vulgaris cases respectively. One case presented with crusted scalp lesions only (Fig. 1). Direct immunofluorescence study was done on 4 cases of pemphigus vulgaris and all of them

were positive for inter cellular deposits of IgG intraepidermally. Tzanck smear test was done for 5 cases of pemphigus vulgaris and in all 5 cases the Tzanck smear test was positive for the presence of acantholytic cells (Table 4 and 5).

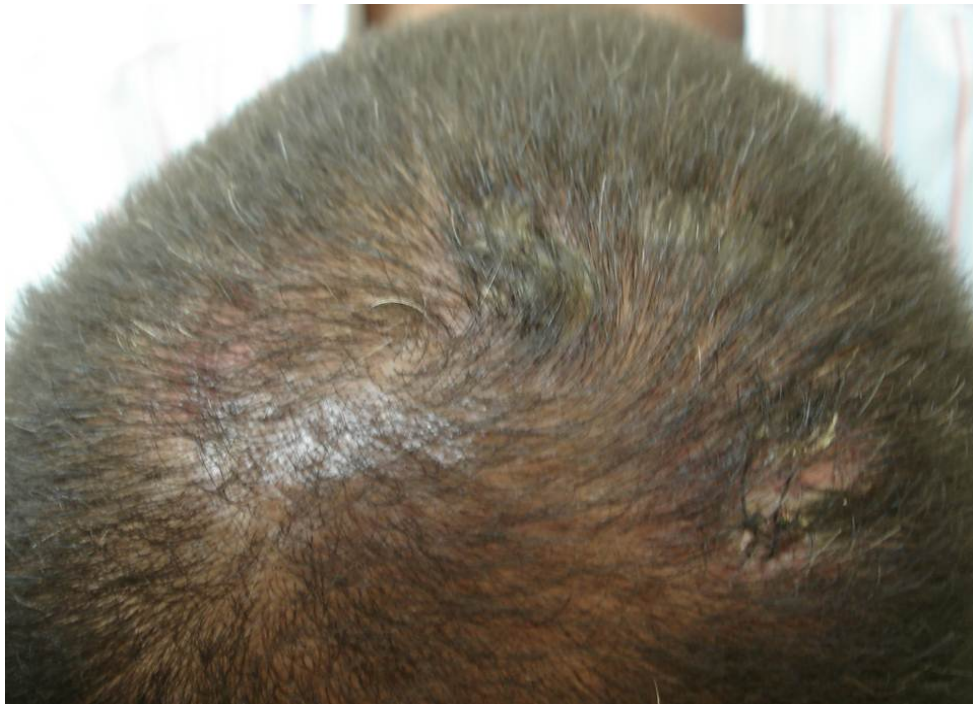

Figure 1. Crusted scalp lesions (localized scalp pemphigus vulgaris)

The other immunobullous diseases in our study in decreasing frequency were pemphigus foliaceus, herpes gestationis, dermatitis herpetiformes, chronic bullous dermatosis of childhood, linear IgA dermatosis and lichen planus pemphigoides.

All 6 cases of pemphigus foliaceus except one case presented with erosions and ruptured flacid blisters over the upper trunk, face and extremities without oral or other mucous membrane lesions. There were 4 female patients and two males with age range from

29-72 yr. one of the cases a 29 yr. old female had localized crusted lesions on the face and neck only. Histopathological changes showed upper epidermal subcorneal split with acantholysis containing few acantholytic cells and dermal inflammatory cell infiltrate containing neutrophils and eosinophils (Fig. 2). Immunofluorescence study was done on the case with localized lesions to the face and neck only and showed intraepidermal intercellular deposits of IgG in a lacelike pattern.

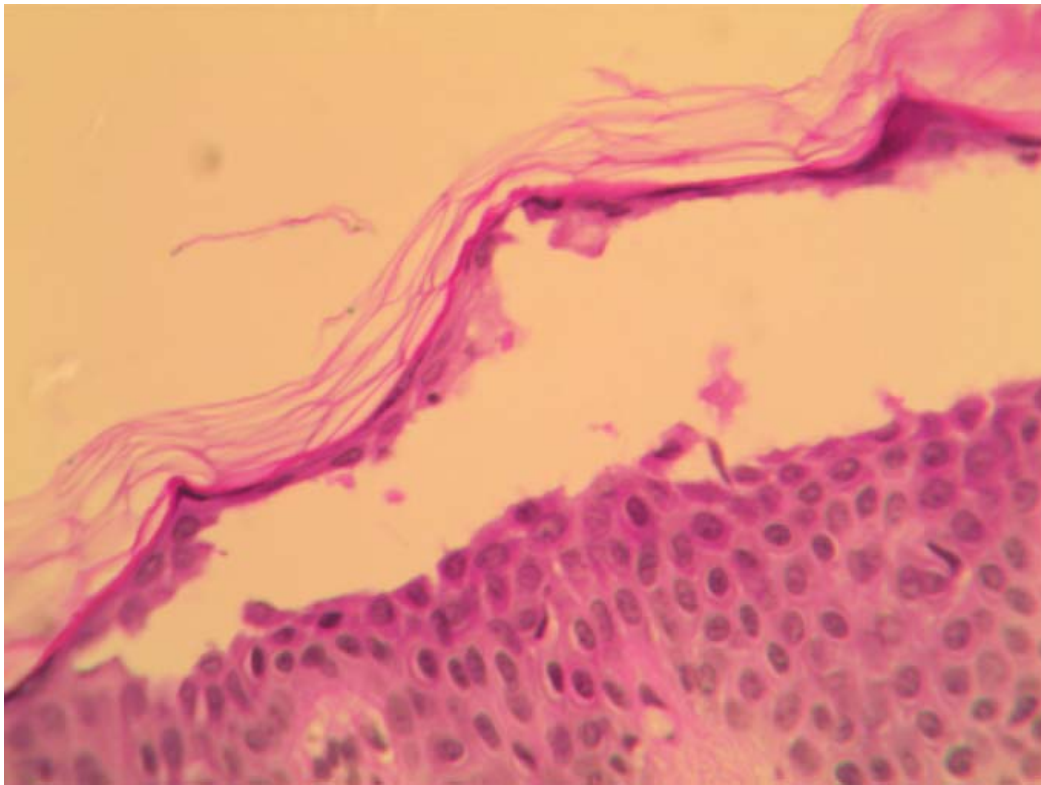


Figure 2: Upper intra-epidermal acantholytic split containing acantholytic cells (Pemphigus foliaceus)

Three cases of pemphigoid gestationis presented with severely itchy urticarial skin rash with tense blister during pregnancy on trunk and extremities, the fourth case presented with severely itchy urticarial rash without blisters, the patients age was between 21-42 yr. Histopathological changes showed subepidermal bullus containing eosinophils and neutrophils in three cases with clinically tense blisters.

These cases showed Papillary dermal edema and moderately dense dermal inflammatory cell infiltrate containing eosinophils with eosinophilic spongiosis (eosinophils in the epidermis with spongiosis). Immunofluorescence study was done on one case that did not show frank blister (to rule out the possibility of pruritic urticarial plaques and papules of pregnancy) and it was positive for linear deposits of IgG and C3 at the

dermoepidermal Junctions.

Cases with dermatitis herpetiformia were two females and one male with age range from 35-65 yr. All of them presented with severely itchy papules and vesicles on the trunk, extremities and face with grouping of lesions and excoriation. Histopathological changes were upper dermal edema and upper dermal inflammatory infiltrate containing numerous neutrophils with collection of neutrophils in the dermal papillae (Papillary neutrophilic micro abscesses). In one case there was a subepidermal split containing fibrinoid material. Immunofluorescence study was done in two cases and showed positive deposits of granular IgA at the tip of dermal papillae in one case.

Cases of chronic bullous disease of childhood were one 7yr. old female and one 4 yr. old male presented with itchy grouped vesicles and blisters on the groin, periumbilical

area, and extremities with formation of rosettes of new lesions. Histopathological changes were subepidermal bullae containing neutrophils and moderately dense neutrophil rich inflammatory cell infiltrate containing eosinophils. Immunofluorescence study was done on the two cases and was positive in one case for deposits of linear IgA at the dermoepidermal junction.

There was one case of linear IgA disease in a female patient (28 yr) with severely itchy grouped vesicobullous lesions forming rosettes. Histopathological changes were subepidermal bullus containing neutrophils

and moderately dense superficial perivascular inflammatory cell infiltrate rich in neutrophils and containing eosinophils. Direct immunofluorescence study was done on this case and showed positive deposits of IgA at the dermoepidermal junction.

There was one case of lichen planus pemphigoides in a female patient (12 yr) with severely itchy bullous and lichenoid lesion with typical mouth lesions of lichen planus. Histopathological changes showed subepidermal bullous containing eosinophils and neutrophils with upper dermal inflammatory cell infiltrate containing eosinophils and neutrophils.

Table 4. Clinical features of pemphigus vulgaris cases at presentation

Feature		No. of cases	Percentage
sex	Male	6	43%
	Female	8	57%
Age	<30yr.	2	14%
	30-50yr.	7	50%
	>50yr.	5	36%
Mucous membrane involvement		13	93%
Skin flacid blisters		12	
Site of lesion	Trunk chest	10	71%
	extremities	6	43%
	Scalp only	1	7%
Associated diseases	Tumor	1	7%
	D.M	1	7%

Table 5. Histopathological features of pemphigus vulgaris cases

Feature	Histopathological changes	No. of cases	Percentage
Level of split	subbasal	14	100%
Bullus content	Acantholytic cells Neutrophils, eosinophilis lymphocytes	14	100%
Adjacent epidermis	Spongiosis	6	43%
Involvement of adnexae	Acantholysis	3	21%
Dermal infiltrate	Neutrophils, eosinophils and lymphocytes	14	100%
Others	Prominent villi	3	21%
	acanthosis	2	14%
Associated diseases	D.M	1	7%

	Tumor	1	7%
--	-------	---	----

Discussion:

Immunobullous skin diseases are a group of autoimmune disorders caused by pathogenic autoantibodies directed against antigens in the intercellular structures between keratinocytes (Desmosomes), or in the dermo epidermal junction (basement membrane zone)⁽¹⁾. According to the targeted molecule or organelle, molecular classification has been suggested². These diseases can be divided into intra epidermal and sub epidermal groups. Immunobullous intra epidermal skin diseases include the pemphigus group and its variants⁽²⁾ e.g. pemphigus vulgaris and pemphigus vegetans, pemphigus foliaceus, pemphigus erythematosus, drug induced pemphigus, IgA pemphigus, and paraneoplastic pemphigus.

Sub epidermal immunobullous diseases include bullous pemphigoid, pemphigoid gestationis, cicatricial pemphigoid, linear IgA disease, epidermolysis bullosa acquisita, bullous lupus erythematosus, lichen planus pemphigoides and chronic bullous disease of childhood.

In our study, we have cases representing both subgroups.

The prevalent number of cases in our study were bullous pemphigoid cases followed by pemphigus vulgaris cases which agrees with Langan et al. study⁽³⁾. The incidence of bullous pemphigoid is increasing and the mortality in patients with bullous pemphigoid is twice more than in normal population⁽³⁾. The spectrum of clinical presentation in bullous pemphigoid include tense blisters, urticarial plaques and prurigo-like eczematous lesions⁽⁴⁾. In our study the majority of patients had tense blisters with urticarial plaques and eczematous

lesions. Similar results were reported by Leena et al.⁽⁵⁾.

Two patients had persistent urticarial plaques without blisters. Urticarial stage of bullous pemphigoid has been reported⁽⁴⁾. Involvement of mucous membrane is uncommon in bullous pemphigoid⁽⁶⁾. Only one of our patients with bullous pemphigoid had oral mucous membrane lesions.

In our study bullous pemphigoid cases are more common in older age group patients, extremities are common sites of involvement followed by trunk. This conforms with other studies^(3,5) with mild female predominance as reported by Langan et al.⁽³⁾.

One of our bullous pemphigoid patients was a 4 year old male. Childhood bullous pemphigoid has been reported^(7,8). Associated diseases with bullous pemphigoid in our study were diabetes Mellitus in 5 patients and one case of colon carcinoma. Association of bullous pemphigoid with internal diseases including diabetes mellitus and malignancy has been debated and studies showed conflicting results but has not been proven yet^(6,9).

Histopathological changes in early lesions of bullous pemphigoid show papillary dermal edema, cell-poor or cell-rich perivascular lymphocytic and eosinophilic infiltrate⁽¹⁰⁾. The cell-poor pattern (Fig. 3) is observed when blisters develop on relatively normal skin and the cell-rich pattern when the blister arise on erythematous skin⁽¹⁰⁾. In the cell-poor pattern there is usually scant perivascular lymphocytic inflammation with few eosinophils, In the cell-rich pattern numerous eosinophils intermingled with lymphocytes and neutrophils are present in the dermal

inflammatory infiltrate⁽¹⁰⁾. Eosinophilic spongiosis can occur⁽¹⁰⁾. The blister arises at the dermoepidermal junction and it is sub epidermal, which usually contain eosinophils, neutrophils and fibrin^(10,11,12) with preservation of the dermal papillae⁽¹¹⁾. The majority of our cases showed this picture. Epithelial regeneration may result in an intra epidermal location of older blisters⁽¹⁰⁾. In our study, we had one case of cell-poor pattern of bullous pemphigoid, four cases with epithelial regeneration and one case with histopathological picture of early stage of bullous pemphigoid with papillary dermal edema and eosinophil rich inflammatory cell infiltrate without blister. The diagnosis of this case was proved by direct immunofluorescence study with positive deposition of linear IgG and C3 at the dermoepidermal junction (to rule out other possible diagnosis with similar routine histological picture).

Almost all patients with bullous pemphigoid demonstrated positive deposition of IgG and or C3 on direct immunofluorescence study of the perilesional skin^(12,13).

Immunofluorescence study is diagnostic and is needed to prove the diagnosis if there is no histological evidence of blisters, as in one of our cases in this study.

Newer techniques like immunoprecipitation technique, Western blot analysis⁽¹⁴⁾ and ELISA^(13,15) are increasingly being used in the diagnosis of immunobullous diseases.

However, these investigations are complex and expensive. Immunofluorescence still retains its role in this field⁽¹³⁾.

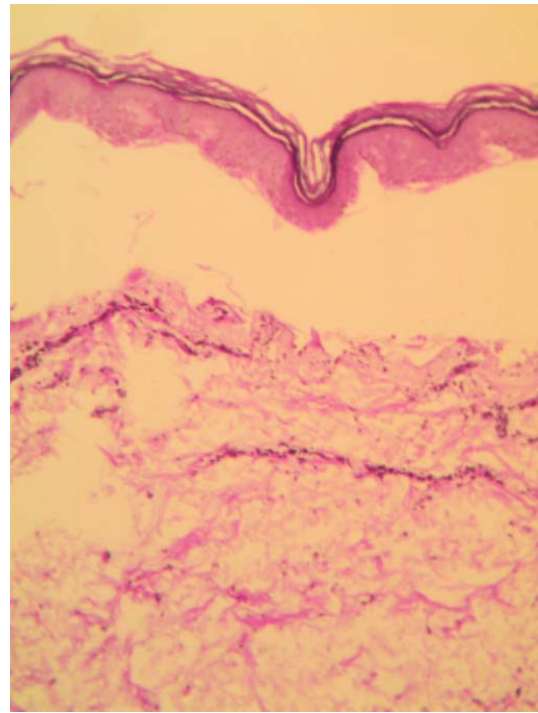


Figure 3: Cell-poor sub epidermal blister (cell-poor bullous pemphigoid)

The second most frequent disease in our study is pemphigus vulgaris. we had 14 patients with pemphigus vulgaris. Pemphigus vulgaris affects younger age group patients as compared with bullous pemphigoid but its incidence increases with age also⁽³⁾. Mortality in patients with pemphigus vulgaris is three times more than that of normal population⁽³⁾. Usually male and female affected equally but as in our study, some studies showed mild female predominance⁽³⁾ Essentially all patients with pemphigus vulgaris develop painful erosions of the oral mucosa, in addition to the flacid easily ruptured blister on skin^(4, 12, 16). In some patients, oral lesions are the only clinical manifestation of pemphigus vulgaris^(4,12). Localized pemphigus vulgaris of the scalp has been reported⁽¹⁷⁾. The vast majority of our patients had skin and oral mucous membrane lesions, only one patient had the localized scalp form without skin or mucous membrane lesions (Fig.1 and 4).

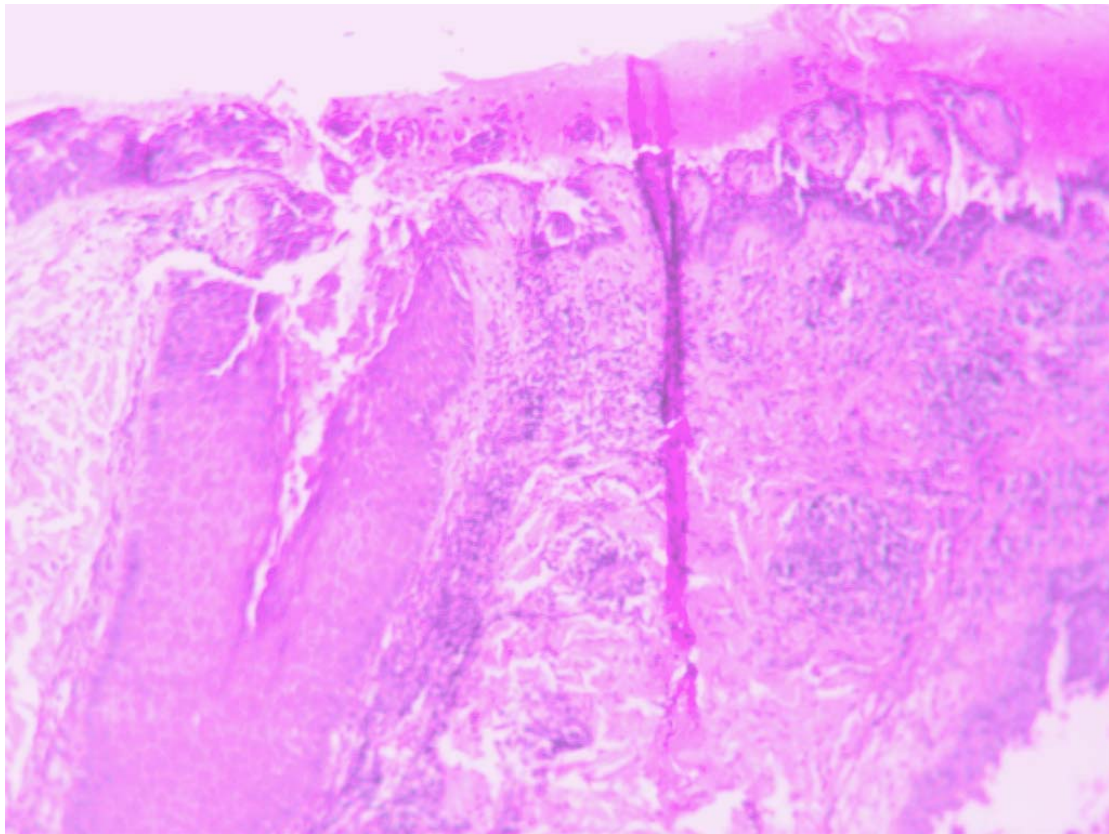


Figure 4: Suprabasal acantholytic split containing acantholytic cells and involving the hair follicle (localized scalp pemphigus vulgaris)

Another one female patient of our patients in the study had only oral mucous membrane lesions without skin lesion. As in our study, a study showed that the distribution of the skin lesions in pemphigus vulgaris is more on the trunk followed by the extremities⁽⁵⁾. Pemphigus vulgaris can be associated with some immune diseases and tumors⁽¹⁸⁾. In our series, one case was associated with thyroid tumor and another case was associated with diabetes miletus.

Histopathological changes in pemphigus vulgaris include; intra epidermal suprabasal bullae with acantholysis containing acantholytic cells that may contain inflammatory cells, dermal inflammatory cell infiltrate of lymphocytes, eosinophils and neutrophils, adjacent epidermis may show spongiosis and downward growth of epidermal strands giving rise to villi formation may occur^(10,11). Acantholysis may extend into adnexal structures 10 Fig. 5).

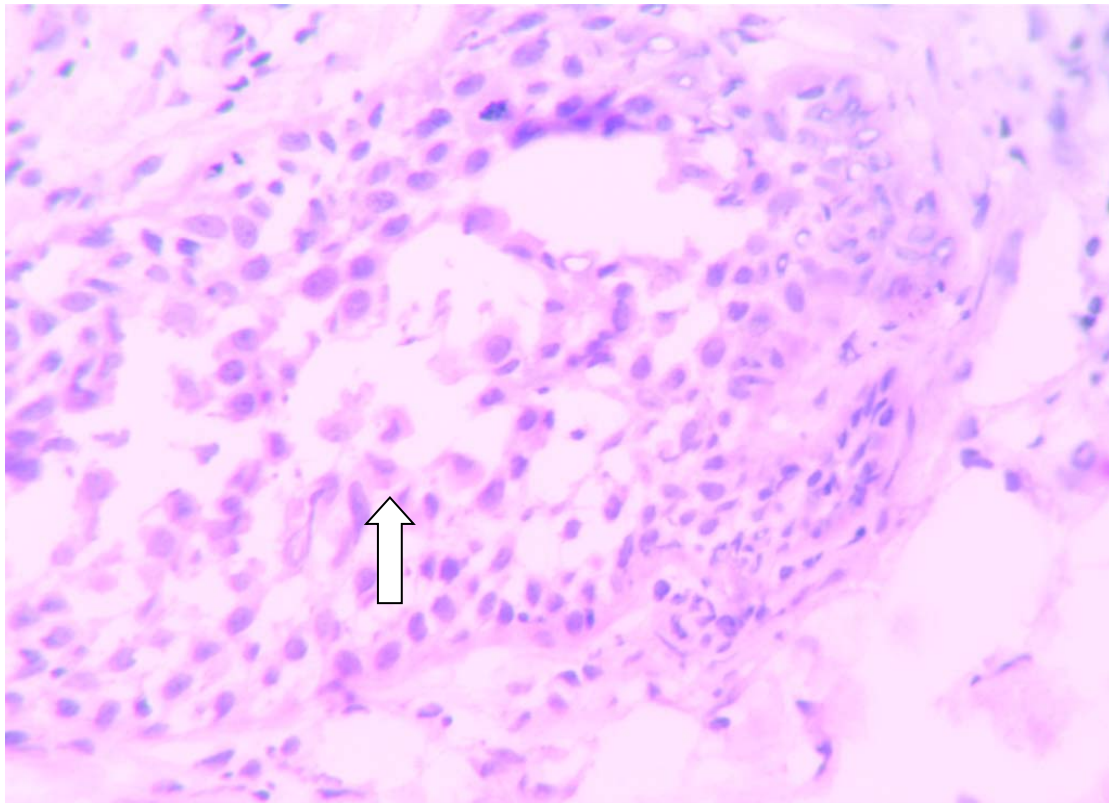


Figure 5: Acantholysis (Arrowed) involving the hair follicle in localized scalp pemphigus vulgaris

All these histopathological changes were seen on our pemphigus vulgaris cases in this study. In addition, we had two patients with acanthosis and this has been shown in Leena et al series⁽⁵⁾. Cytological examination using a Tzanck smear test was useful for the rapid demonstration of acantholytic cells in the blister of pemphigus vulgaris⁽¹⁹⁾.

In our cases, Tzanck smear was done in 5 cases and it was positive in all these five cases and proved to be helpful. Direct immunofluorescence study is usually positive in 100% of cases in pemphigus vulgaris and show positive deposition of IgG intraepidermally between the keratinocytes in a lace-like pattern and it is a diagnostic test⁽¹³⁾.

In our study, direct immunofluorescence was

done only in four cases of pemphigus vulgaris and proved to be positive in all of them.

ELISA is a new diagnostic technique for pemphigus vulgaris⁽²⁰⁾. This test had not been used in our study.

Pemphigus foliaceus is a rare disease that affects both sexes equally. Clinically it presents with crusted lesions and superficial erosions over the chest, back, shoulder, scalp and face⁽²¹⁾. In some cases the lesions localize to one site and persists for long time²¹. One of our patients had localized lesions on the face and neck only. Oral mucous membrane lesions is very rare in pemphigus foliaceus^(12, 21). Non of our patients had oral mucous membrane lesions

Histopathological changes in pemphigus foliaceus are upper intra epidermal blister with a cantholysis at the level of granular cell layer which may contain neutrophils and eosinophils^(10,21) (Fig. 2). Immunofluorescence study is important to differentiate it from a rare form of pemphigus called IgA pemphigus^(13,21). New diagnostic technique like ELISA can be used⁽²²⁾.

Pemphigoid gestationis (Herpes gestationis) occurs during pregnancy and recurs in subsequent pregnancy in more than 90% of cases⁽²³⁾. One of our patients with pemphigoid gestationis had recurrent disease.

The clinical, histopathological and immunopathological features of pemphigoid gestationis is similar to other pemphigoid group of blistering diseases⁽²³⁾.

Usually patients present with severely itchy persistent urticarial skin rash then develop tense blister on the periumbilical areas^(4,23).

All our patients had severe itching. Usually patients have no mucous membrane lesions⁽²³⁾. None of our patients had mucous membrane lesions.

Direct immunofluorescent study is very important to differentiate it from other relatively benign pregnancy dermatosis called pruritic urticarial plaques and papules of pregnancy. Positive serum test through indirect immunofluorescence for HG factor (Herpes gestationis factor) is also helpful for diagnosis⁽²³⁾. ELISA test can be used too.

Dermatitis herpetiformes is a chronic disease with relapsing course, pruritic polymorphic lesions and typical

histopathological and immunopathological findings^(12, 24). It is a skin expression of gluten sensitive disease²⁴.

The majority of patients are in their 3rd decade of life⁽²⁴⁾. Two of our patients are 40 and 35 year old. Usually patients present with severely itchy polymorphic rash of grouped papules, vesicles and excoriation on extensor surfaces of extremities, trunk and face^(12,24). All our patients had severe itching. Histopathological changes included sub epidermal blister with collection of neutrophils at tips of dermal papilla (papillary neutrophilic micro abscesses) and dermal inflammatory infiltrate containing neutrophils^(10,24).

Immunofluorescence study is the gold standard for the diagnosis of dermatitis herpetiformes. Direct immunofluorescence shows granular deposition of IgA at tips of dermal papilla^(13,24). Serologic tests for early detection of gluten sensitive disease including dermatitis herpetiformes like; IgA anti-tissue Transglutaminase antibody and IgA endomysial auto antibodies should be done⁽²⁴⁾.

Autoimmune disease and lymphoma can be associated with dermatitis herpetiformes⁽²⁴⁾. None of our patients had any association.

Chronic bullous disease of childhood is the most common acquired blistering disorders of children and is characterized by linear IgA staining of the basement membrane zone (BMZ) on direct immunofluorescence⁽²⁵⁾. Diagnosis is confirmed by characteristic histopathological changes of sub epidermal blister containing neutrophils and a neutrophil rich inflammatory cell infiltrate and linear deposition of IgA at basement membrane zone^(13,25). Prognosis is generally favorable with spontaneous remission usually occurring

by puberty. However cases with severe morbidity and cases persisting into adulthood have been reported⁽²⁵⁾. We have two patients in our series with typical features of chronic bullous disease of childhood. Linear IgA disease is one of the rarer sub epidermal blistering diseases⁽²⁶⁾. Linear IgA disease is a chronic, acquired autoimmune that is characterized by sub epidermal blister containing neutrophil rich dermal infiltrate and linear deposition of IgA at basement membrane zone⁽²⁶⁾. In addition to IgA deposition concomitant deposition of IgG at basement membrane zone has been reported⁽²⁷⁾. Direct immunofluorescence study and salt-split test are helpful to differentiate it from other epidermolysis bullosa acquisita¹³. We have one case in our study proved by direct immunofluorescence.

Lichen planus pemphigoides is a rare controversial disease which thought by

majority to be a concurrence of bullous pemphigoid and lichen planus with clinical, histopathological and immunological features suggesting both⁽²⁸⁾. There are convincing reports which identify a separate 200 kd Ag by immunoblotting in patients with lichen planus pemphigoids⁽²⁹⁾. Our patient in the study is a 12 year old female with typical clinical picture of lichen planus and tense blisters.

Conclusion

Immunobullous diseases are relatively rare but a serious group of skin diseases with a diagnostic clinical and histopathological picture that helps in their early diagnosis. Some rare forms and features of these diseases have been described. Some of them were included and discussed in our study like; localized pemphigus vulgaris of the scalp, cell-poor bullous pemphigoid, childhood bullous pemphigoid, lichen planus pemphigoides and acantholysis involving the hair follicles.

References

- Burgeson RE, Christiano AM. The dermal-epidermal junction. *Curr Opin Cell Biol* 1998; 9: 651-8.
- Diya E Mutasim. Management of autoimmune bullous diseases: pharmacology and therapeutics. *J Am Acad Dermatol* 2004; 5: 859-77.
- SM Langan, L Smeeth, KM Fleming, CJP Smith, J West. Bullous pemphigoid and pemphigus vulgaris – incidence and mortality in the UK: population based Cohort study. *BMJ* 2008, 337: a 180.
- Kneisel A, Hert LM. Autoimmune bullous skin disease. Part 1: clinical manifestations. *J Dtsch Dermatol Ges* 2011; 9 (10): 844-56.
- Leena JB, Chandrashekar M, Vijaya B, Sunila R, Manjunath GV. A clinicopathological study of immunobullous lesions of the skin. *Adv Lab Med Int.* 2012; 2 (2): 49-60.
- L. Hodge, RA Marsden, MM Black, B. Bhogal, MF. Corbett. Bullous pemphigoid: The frequency of mucous membrane involvement and concurrent malignancy related to indirect immunofluorescence findings. *British Journal of Dermatology*, 1981; 105: 65-69.
- Das D, Das A, Debbarman P. Childhood bullous pemphigoid, *Indian Pediatr.* 2013 Dec 8; 50 (12): 1179.
- Sharma R, Nadeem M, Chandra M. Bullous pemphigoid in childhood. *Indian J Dermatol Venereol Leprol* 1996, 62; 100-2.
- Hana Jedlickova, Milos Hlubinka, Tomas Pavlik, Vera Semradova, Eva Budinska, Zdenek Vlasin. Bullous pemphigoid and internal diseases – A case-control study. *European Journal of Dermatology.* 2010; 20 (1): 96-101.
- David Elder, Rosalie Elenitsas, Christine Jaworsky, Bennett John son, Jr. *Levers Histopathology of the skin.* Lippincott – Raven; 8th edition 1997; 209-253.
- Bernard Ackerman, Nidhi Chongchitnant, Jorge Sanchez, Ying Guo, Bruce Benin, Martin Reichel, M. Barry Randall. *Histologic diagnosis of inflammatory skin diseases, An Algorithmic Method Based on pattern Analysis* Williams and Wilkins. Second edition 1997 page 238.

12. Jean L Bologna, Joseph Jorizzo, Ronald Rapini et al. Second Edition Dermatology MOSBY 200; 1: 403-488.
13. Zahida Rani, Ijaz Hussain. Immunofluorescence in immunobullous diseases. Journal of the Pakistan Association of Dermatologists 2003; 13: 76-88.
14. Guidice GJ, Diaz LA. New Laboratory methods in the investigation of bullous diseases. Dermatol Clin 1993; 11: 419-27.
15. Zillikens D, Rose PA, Balding SD et al. Tight clustering of extra cellular B.P 180 epitopes recognized by bullous pemphigoid auto antibodies. J Invest Dermatol 1997; 109: 573-9.
16. Kazne Yoshida, Yuijiro Takae, Histosh Saito et al. Cutaneous type of pemphigus vulgaris: A rare clinical photo type of pemphigus vulgaris. JAAD, 2005, 52 (5); 837-845
17. Lapiere K, Caers S, Lambert J. A case of long standing localized pemphigus vulgaris of the scalp. Dermatology 2004, 209: 162-163.
18. Eleonora Ruocco, Ronni Wolf, Vincenzo Ruocco, et al. Pemphigus: Association and management guidelines: facts and controversy. Clinics in Dermatology 2013, 31 (4): 382-390.
19. Wheeland JH, Burgdorf WHC, Hoshov RA. A quick Tzank test. J Am Acad Dermatol 1983; 8, 258.
20. Nishikawa T. Desmoglein ELISAs: a novel diagnostic tool for pemphigus. Arch Dermatol 1999; 135, 195-7.
21. Kirl A, James BS, Donna A Culton and Luis A Diaz. Diagnosis and clinical features of pemphigus foliaceus. Dermatol clin 2011 July; 29 (3): 405-412.
22. Ishiik, Amagia A, Hall et al. Characterization of autoantibodies in pemphigus using antigen-specific enzymelinked immunosorbent assay with baculovirus expressed recombinant desmoglein. J Immunol 1997, 159; 2010-2017
23. Marina Flangini Cobo, Claudia Ginl: Santi, Celina Wakisaka Marula et al. Pemphigoid gestationes: clinical and Laboratory evaluation. Clinics (Sao Paolo); 2009; 64 (11): 1043-1047.
24. M Caproni, E Antiga, L Melani et al. Guidelines for the diagnosis and treatment of dermatitis herpetiformes. Journal of the European Academy of Dermatology and Venereology. 23 (6): 633-638, 2009.
25. Mintz EM, Morel KD. Clinical features, diagnosis and pathogenesis of chronic bullous disease of childhood. Dermatol Clin, 2011; 29 (3): 459-62.
26. Venning VA. Linear IgA disease. Clinical presentation, diagnosis and pathogenesis. Dermatol Clin 2011; 29 (3): 453-8.
27. Chan LS, Traczyk T, Taylor TB et al. Linear IgA bullous dermatosis – characterization of a subset of patients with concurrent IgA and IgG anti-basement membrane antibodies. Arch Dermatol 1995; 131 (12): 1432-7.
28. Vibhu, Disnesh Koranne, RV. Lichen planus Pemphigoides in an Indian female. Indian Journal of Dermatology 2005, 50 (4): 224-226.
29. Davis A, Wojnarowsha F, Bhogal B et al. Lichen planus pemphigoides and its relationship to pemphigoid, Br. J Dermatol 1989; 120; 296.

دراسة تحليلية للعلامات السريرية والباثولوجية المجهرية التشخيصية لـ 55 حالة من الأمراض المناعية الفقاعية

عوض حسن الطراونه¹

1- استاذ مساعد، استشاري امراض جلديه وعلم امراض الجلد، كلية الطب، جامعه مؤتة، الأردن.

الملخص

الخلفية: الامراض الجلدية الفقاعية المناعية هي مجموعته خطيره من الامراض الجلدية والتي تظهر بأشكال متنوعة وتحتاج الى التشخيص المبكر لضمان نتائج أفضل في المعالجة. نحتاج إلى التقييم السليم من الناحية السريرية والباثولوجية التشخيصية (تحت المجهر) لضمان الوصول إلى التشخيص الصحيح. لذلك من المهم تبادل الخبرات وتبسيط الضوء على هذا النوع من الأمراض الجلدية.

الأهداف: تفحص الأمراض الجلدية المناعية الفقاعية من الناحية السريرية والباثولوجية التشخيصية (المجهرية) كمجموعة ومدى انتشارها في منطقتنا وتبادل الخبرات من اجل التشخيص السليم والمبكر لها.

الأسلوب والأدوات: تم شمول جميع الحالات الجلدية المناعية الفقاعية التي تم تشخيصها في مراكز تحويله في الأردن، عمان (مدينة الحسين الطبية ومستشفى الجامعة الأردنية) وكذلك في القطاع الخاص في الفترة من كانون الثاني 2000م إلى كانون الثاني 2012م في الدراسة حيث تم تحليل ودراسة جميع الحالات من الناحية السريرية والباثولوجية (المجهرية). باستعمال الصبغة المعتادة لصبغة الأنسجة و(هي الميموتوكسلين والايوسين). كما تم فحص ودراسة التآلق المناعي (Immunoflourescence) في 16 حالة وفحص لطخة تزانك (Tank smear) بعد صبغه بصبغة جيمزا في 5 حالات.

النتائج: في الفترة من كانون الثاني 2000م إلى كانون الثاني 2012م تم تشخيص ما مجموعه 55 حالة من مختلف الامراض الجلدية المناعية الفقاعية من أصل 2156 خزعة جلدية تم عملها وفحصها في تلك الفترة. من هذه الحالات كان عدد الذكور 21 حالة وعدد الاناث 34 حالة ونسبة الذكور إلى الاناث (2:1.2)، اعمار المرضى تراوحت من 4-85 سنة. توزيع الامراض الجلدية المناعية الفقاعية تنازليا وحسب نسبة حدوثها كانت كالتالي: الداء الفقاعي (Bullous pemphigoid).

24 حالة بنسبة 44%، الفقاع الشائع 14 حالة بنسبة 25%، الفقاع الحريبي 5 حالات بنسبة 9% التهاب الجلد الحملي الفقاعي 4 حالات بنسبة 7%، التهاب الجلد الحثلي الشكل (Dermatitis) herpetiformes 3 حالات، الجلاد الفقاعي الطفولي المزمن حائتين، الفقاع الحمامي حائتين، الجلاد الفقاعي ايح الف الطولي (linear IgA bullousdermatosis) حاله واحده والحزاز المنبسط الفقاعي حالة واحدة. العلامات الباثولوجية التشخيصية المجهرية كانت مميزة وقطعيه من حيث التشخيص النهائي في معظم الحالات. فحص لطخة تزانك كان مفيداً في حالات مجموعة الفقاع. اظهرت الدراسة حالات نادرة من مرض الفقاع الشائع التي تصيب فروة الرأس فقط، وكذلك تم رصد بعض العلامات الباثولوجية المجهرية للداء الفقاعي مثل الحالات عديمية الخلايا الالتهابية وكذلك انكشاف حليمات الأدمه

الخلاصة: الأمراض المناعية الفقاعية الجلدية هي امراض جلدية خطيرة تصيب كافة الاعمار، ويؤدي الفحص السريري والباثولوجي المجهر السليم والصحيح إلى التشخيص النهائي. ولكن في بعض الحالات يلزم عمل فحص دراسة المعان المناعي للتوصل إلى التشخيص الصحيح. بعض الفحوصات البسيطة مثل فحص لطخة تزانك مفيدة في بعض الحالات.

الكلمات الدالة: الأمراض المناعية الفقاعية، الأردن.